

Radiographic Appearance of the Chest in Emphysema

WILLIAM M. THURLBECK¹ AND GEORGE SIMON²

Accuracy of the radiologic diagnosis of emphysema was assessed in 696 patients from whose lungs paper-mounted whole-lung sections had been made. Emphysema was diagnosed radiographically primarily on the basis of arterial deficiency. In addition, lung length, lung width, size of the retrosternal space, heart size, and diaphragm position were recorded from the chest films. Recognition of emphysema was poor when radiographs of inadequate quality were included (anteroposterior films or films from patients with acute or chronic lung disease). When these films were excluded, only occasional radiographs from patients without emphysema or with mild emphysema were thought to have emphysema radiologically. Of the patients with moderately severe and severe emphysema, 41% were diagnosed as having emphysema, as were two-thirds of those with the most severe grade of emphysema. For a given grade of emphysema, the radiologic diagnosis of emphysema was made more frequently when patients had severe chronic airflow obstruction. Emphysema was usually most severe in the zones of the lung in which emphysema was radiologically apparent. Centrilobular emphysema was usually present when emphysema was diagnosed radiologically in the upper zones of the lung, and panacinar emphysema was usually present when emphysema was diagnosed in the lower zones. Lung length and the size of the retrosternal space increased, the level of the diaphragm lowered, heart size decreased, and lung width was unchanged as emphysema became more severe. Lung length and diaphragm level were the most discriminating measurements, followed by size of the retrosternal space. No combination of radiologic variables was found that recognized emphysema better than the subjective diagnosis of emphysema based on arterial deficiency. Radiologic lung dimensions are related to stature; for given stature these measurements are larger in men and women.

Introduction

Despite the fact that the literature concerning the accuracy of the radiologic diagnosis of emphysema is controversial, many standard radiologic [1] or medical [2] textbooks and monographs [3] place considerable reliance on the chest film in the diagnosis of emphysema. The type A form [4] of chronic airflow obstruction is often defined in large part by the presence of emphysema as diagnosed radiologically, and many physiologic studies of "emphysematous" or "bronchitic" patients have used the presence or absence of radiologic emphysema to determine the category in which the patient should be placed. Since emphysema is defined anatomically, it can only be recognized with satisfactory precision at necropsy, and thus the accuracy of the radiologic diagnosis of emphysema must be assessed against the morphologic diagnosis of emphysema rather than against a functional or clinical diagnosis.

Both the radiologic diagnosis of emphysema and the assessment of the amount of emphysema present in the lungs are subjective, and observer bias could play a large part in determining the observed relationship between the two. In addition, many of the reported studies are limited to small numbers of cases and sometimes only contain, or are biased toward containing, an excess of patients with chronic airflow obstruction. We thus have restudied the problem using a much larger group of cases than previously reported, including a large number of random cases. We have also taken care to minimize the effect of observer bias and have made objective measurements of certain variables that can be seen on the chest film (lung length, lung width, diaphragm position, size of retrosternal space). These will be referred to subsequently as quantitative radiologic variables. Besides relating these quantitative radiologic variables to the amount of emphysema seen in the lungs, we have been able to relate them to stature and sex of the subjects.

Materials and Methods

The series included 696 necropsies from the Pathology Institute, McGill University, Montreal, Canada. These patients were chosen because paper-mounted whole-lung Gough-Wentworth sections [5] had been made from at least one lung inflated intrabronchially with formaldehyde after death. In addition, antemortem chest radiographs were available. The lungs had been collected for a variety of reasons. In 422 instances, they came from random consecutive necropsies. In 95 instances, the lungs had been collected because of special clinical or pathologic interest; the great majority of this group had detailed tests of pulmonary function. The remainder (179) represented collections made for a variety of reasons including anatomic or functional studies of normal lungs and assessment of the morphologic features of bronchitis or emphysema.

The radiographs used in this study were the best available and closest to the time of the patients' demise. Posteroanterior and lateral films were taken under standard conditions with a 3 m focus-film distance and a 15.24 cm air gap. In 422 instances posteroanterior and lateral films were available. In the remaining patients, 10 had only posteroanterior films and 244 had anteroposterior films (59 of these also had lateral films). The average interval between death and the time the films had been taken was 164 days. The interval was less than 6 months in 78% of the cases and more than 2 years in 4%, the longest interval being 4 years. The interval was the same in patients with and without emphysema. In particular, the time interval was essentially the same in patients with moderately severe and severe emphysema who were not diagnosed radiologically as having emphysema.

The paper-mounted whole-lung sections were randomized and the amount of emphysema assessed by three observers (M.

Received February 11, 1977; accepted after revision December 7, 1977.

¹Department of Pathology, University of Manitoba, Faculty of Medicine, 700 William Avenue, Winnipeg, Manitoba, Canada R3E 0Z3.

² Deceased. Formerly of Royal Post-Graduate Medical School and Brompton Hospital, London, England.

S. Dunnill, R. C. Ryder, and W. M. Thurlbeck) who were unaware of the clinical or radiologic conditions of the patients. The amount of emphysema was assessed subjectively using a standard grading panel on which the amount of emphysema is scored from 0 to 100 [6]. Four examples are shown in figure 1. The mean score of the three observers was used as the score for each lung, and the lungs were placed in emphysema severity groups (ESG) according to the amount of emphysema (table 1).

In many of the subsequent analyses, emphysema severity groups were combined as follows: groups 1-3 = no or trivial emphysema; groups 4-6 = mild or moderate emphysema; groups 7-9, moderately severe or severe emphysema.

A variety of subjective assessments were made of the clinical and necropsy data on these cases. If differences existed between the first and second assessment, a third and final assessment was made.

Lung Disease

On the basis of the amount and type of disease found at necropsy, the lungs were divided into 12 categories. Those in the first six were free of chronic lung conditions (other than bronchitis or emphysema) likely to obscure the radiologic appearance of emphysema. Radiographs were divided into two categories: those with radiologic abnormalities which might obscure the diagnosis of emphysema or radiologic measurements within the lung, and those essentially free of radiologic abnormalities other than those of emphysema. Patients with posteroanterior and lateral films whose lungs were free from chronic lung disease at necropsy and who also had chest films free from changes likely to obscure the radiologic diagnosis of emphysema or to affect other variables were grouped as A1 cases. There were 257 such subjects.

Chronic Airflow Obstruction

The severity of chronic airflow obstruction was assessed, and two categories are used in this study. One group consisted of patients with well documented chronic airflow obstruction who died of other disease. All had a forced expiratory volume in the first second (FEV₁) of less than 40% predicted and maximum mid-expiratory flow rate (MMFR) less than 25% of predicted. The other group consisted of patients who died from chronic airflow obstruction as assessed from clinical and autopsy findings. The majority of patients had pulmonary function tests during life and met the criteria of the former group. Patients with chronic airflow obstruction were further subdivided into those with unequivocal evidence of right ventricular hypertrophy at necropsy and those who, in addition, had unequivocal evidence of right ventricular failure.

Emphysema

One of us (W. M. Thurlbeck) categorized the type of emphysema in each case. Patients with an approximately equal mixture of centrilobular and panacinar or of centrilobular, panacinar, and irregular emphysema were further identified as a subgroup from patients with "other" emphysema, since they turned out to be of particular interest in the radiologic diagnosis of emphysema. In addition, each paper-mounted whole lung section was divided into upper, middle, and lower thirds, and the severity of emphysema was assessed in each on a 0-3 scale using standard grading pictures [6] by the same observer who categorized the type of emphysema.

Chronic Bronchitis

The clinical records were carefully scrutinized for a history of chronic phlegm production, and five categories were recog-

TABLE 1
Emphysema Severity Groups

Group No.	Range of Emphysema Score	No. Cases
1	0	206
2	1-4	150
3	5-14	113
4	15-24	80
5	25-34	39
6	35-44	44
7	45-54	28
8	55-64	14
9	>65	22

nized. The most severe category consisted of unequivocal examples of phlegm production for more than 2 years. No specific cause of mucus hypersecretion, such as bronchiectasis, was found at necropsy in these patients.

Measurements of Stature

Body length was measured using special calipers on necropsies performed in a 1 year period when all lungs were collected for a special study. In the remaining instances, the figure recorded for body length in the necropsy protocol was used.

Radiologic Assessments

The following radiologic variables were measured on posteroanterior films (fig. 2). They have been described in detail elsewhere [7]. Since not all of the cases had measurements of all quantitative radiologic variables and of body length, numbers in the various categories will vary.

Lung length. A horizontal line was drawn through the tubercle of the first rib, and the distance in the midlung as judged by eye was measured from this line to the top of the right dome of the diaphragm.

Lung width. This is the lateral diameter of the thorax between the inner rib surfaces at the level of the top of the right diaphragm.

Diaphragm level. This is the level of the right diaphragm expressed by its position in relation to the ribs, as seen anteriorly. The position was expressed as a whole number or, if closer to the midpoint between ribs, as a half.

Heart size. The transverse diameter of the heart was measured by summing the furthest projection of the heart to the right and the left of the midline.

Retrosternal space. Retrosternal space was measured on the lateral film. This was the horizontal distance from the posterior aspect of the sternum 3 cm below the sternomanubrial junction to the anterior margin of the aorta.

A decision was made as to whether emphysema was present. The diagnosis was made primarily on the basis of arterial deficiency. Vessel size was assessed in all areas (i.e., hilar, midlung, and the outer third of the lung field). Emphysema was considered present when the lung was hypertransradiant with diminished or absent vascularity in the outer lung fields. Interpretation of vascular patterns are subjective; three main abnormalities can be recognized [8]. In the first, the vessels are present but narrowed in most of the lung (fig. 3A). Second, there may be a normal axial pathway but fewer side branches (fig. 3B). Finally, there may be complete absence of vessels (fig. 3C). The concept of marker vessels [8] enables objective measurement of arterial changes. That is, the vessel narrowing or loss can be assessed by comparison with vessels in the less affected or normal areas (figs. 3B and 3C). Diaphragm level

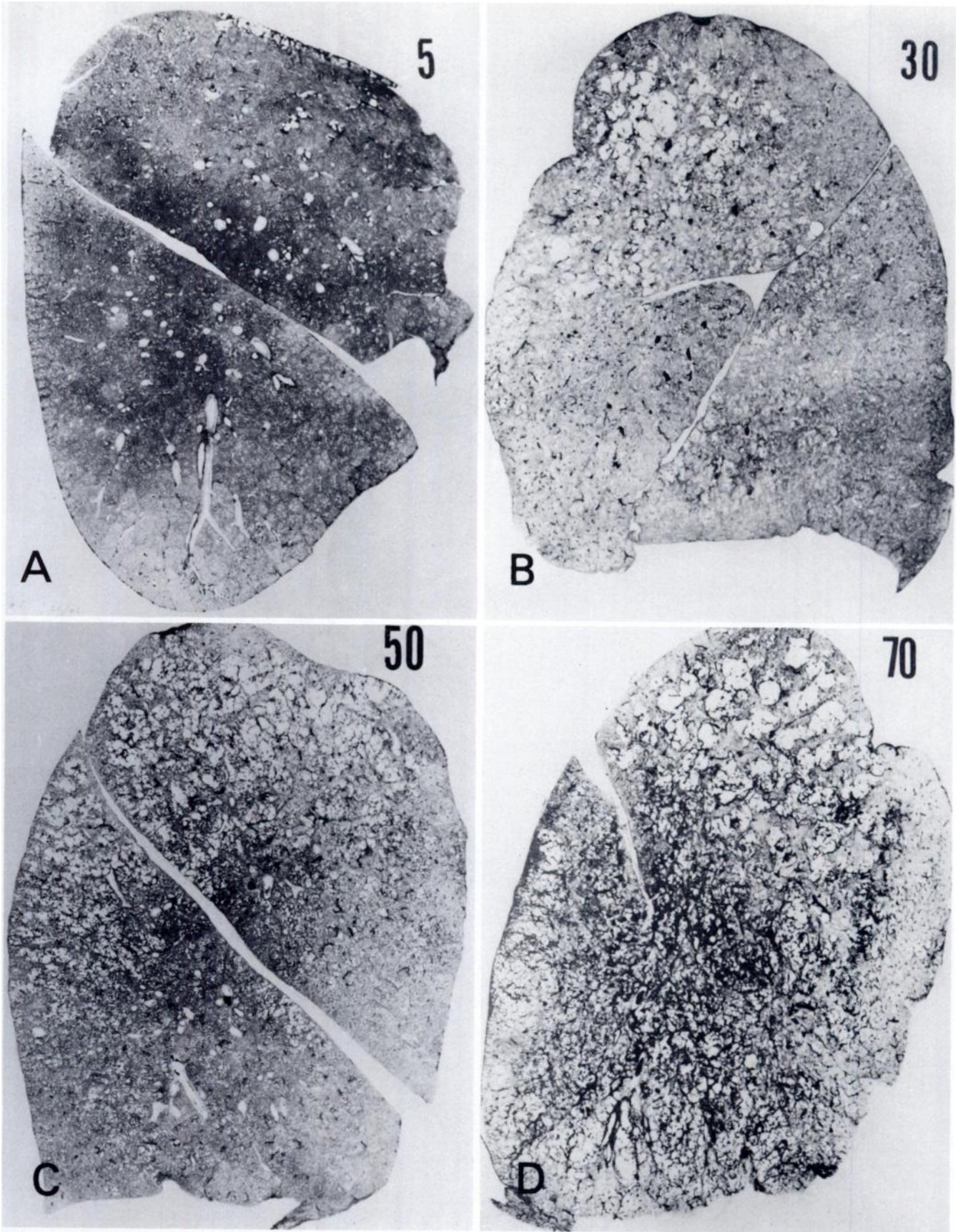


Fig. 1.—Grading standards for emphysema scores of 5 (A), 30 (B), 50 (C), and 70 (D). Average emphysema scores for ESG 1-3, ESG 4-6, and ESG 7-9 were 4, 27, and 59, respectively. Most severe group of emphysema (ESG 9) is shown in D. (Reprinted with permission from [10])

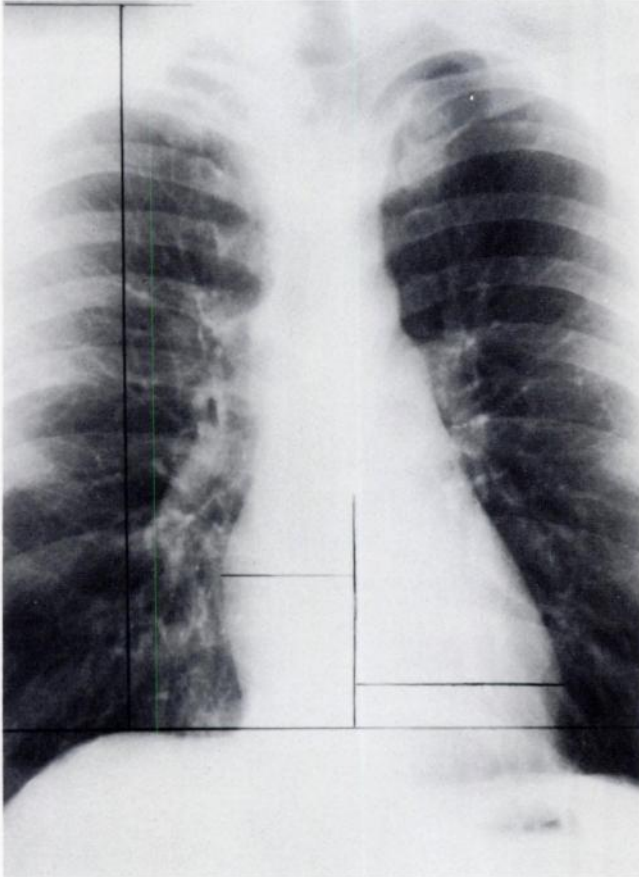


Fig. 2. — Method used to measure length and width of lungs, width of heart, and position of right diaphragm relative to ribs (see text).

and heart size are objective and taken into account. The changes were recorded as widespread (fig. 3A) or localized (figs. 3B and 3C).

Thirty-seven patients were diagnosed radiologically as having emphysema: eight widespread, 24 localized, and five questionable. The arbitrary prior decision was made to include the doubtful cases as positive.

Finally, a repeat radiologic assessment of emphysema was undertaken. The radiographs interpreted as showing emphysema were randomized with the films from patients in emphysema severity groups 7-9. After reexamination, a new statement was made as to the presence or absence of emphysema. The findings were compared, but results of the first reading were used in analyzing the data.

Results

The details of the number of cases in each emphysema severity group diagnosed as having emphysema, average values for radiologic variables in the various ESG groups, the correlation coefficients between stature and lung dimensions, and the zonal distribution of the types of emphysema in the lungs of the patients in this series have been deposited with a documentation service.*

Figure 4 and table 2 illustrate the frequency with which emphysema was diagnosed in the various emphysema severity groups in all cases and in the A1 group.

The radiologic diagnosis of emphysema was made with steadily increasing frequency as the amount of emphysema in the lungs increased. When all cases and all x-rays were considered, occasional patients (one in each of ESG 1 and 2, and two in ESG 3) who had no or trivial emphysema were diagnosed as having emphysema radiologically. In the three groups with the most severe emphysema, the diagnosis was made in 18% of cases in ESG 7, 35% of patients in ESG 8, and 41% of patients in ESG 9.

Table 2 illustrates the effect of various clinical and other variables on the radiologic diagnosis of emphysema. The radiologic diagnosis of emphysema was made more frequently in all cases within each emphysema severity group when the patient had more severe symptoms of chronic airflow obstruction (those with right ventricular hypertrophy or failure and those with well documented severe chronic airflow obstruction). Patients in the group selected and studied because of interest in their lungs had a much higher frequency of chronic airflow obstruction than random cases; the radiologic diagnosis of emphysema was made more frequently in them than in other patients. Also the diagnosis was made more frequently in patient in the "other" emphysema group. When patients in this category were examined more closely, it was found that the increased frequency of the radiologic diagnosis of emphysema was made in lungs with mixed centrilobular and panlobular or centrilobular/panacinar/irregular emphysema. The diagnosis of emphysema was also made more frequently in patients who had chronic bronchitis, but this did not reach statistically significant levels. The differences in the other subgroups were significant for the variables in ESG 7-9 ($P < .01$).

When only the A1 group was considered, the frequency with which the radiologic diagnosis of emphysema was made radiologically showed a marked increase in patients with moderate and severe emphysema. The frequency of the radiologic diagnosis of emphysema increased from ESG 4 onward; in ESG 8 it increased from 35% to 50%, and in ESG 9 from 41% to 67% (fig. 4). There was an increased frequency of the radiologic diagnosis of emphysema in patients with severe chronic airway obstruction compared to the group as a whole in A1 cases as well (table 2). Since fewer cases are present in this table, statistical comparisons have not been made. The table is primarily designed to show that, overall and in all categories, the frequency of the radiologic diagnosis increases when better films and cases are used. However, it should be noted that in the severest emphysema category (ESG 7-9) emphysema was recognized radiologically in only 58% of the cases with obvious clinical chronic airflow obstruction.

Duplicate Readings

Some results of the duplicate readings are shown in table 3. Of the 37 cases, 26 were placed in the same category in the second reading as in the first; if the doubtful readings are regarded as positive, then 30 of the 37 cases were diagnosed similarly in both readings.

* See NAPS Document no. 03212 for four tables of supplementary material. Order from ASIS/NAPS, c/o Microfiche Publications, P.O. Box 3513, Grand Central Station, New York, New York 10017.

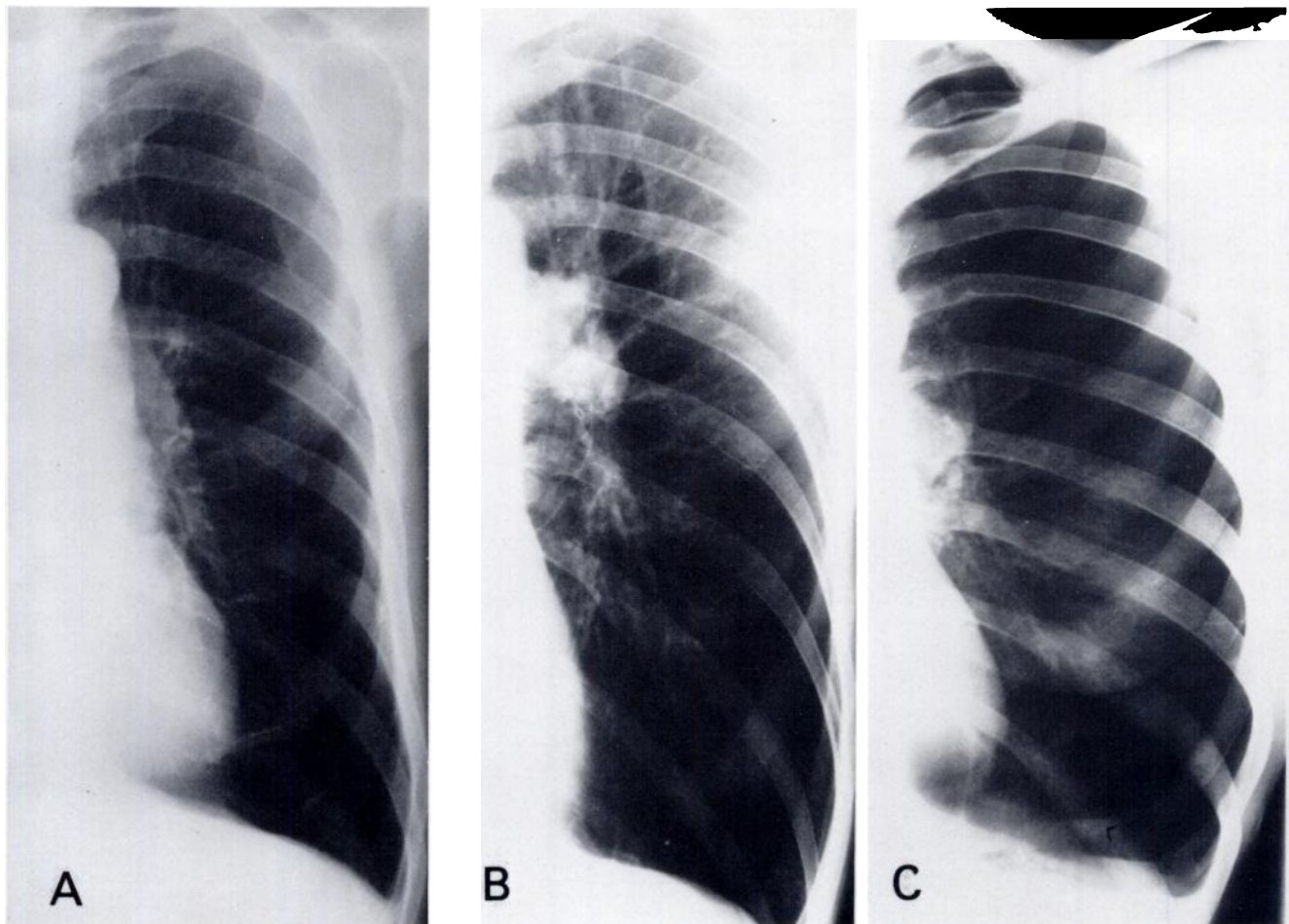


Fig. 3.—Examples of alterations in vasculature used to judge location and severity of emphysema. A, Vessels present but narrowed. Localized emphysema diagnosed in lower lobe. Grade 2 centrilobular emphysema present, ESG 6. B, Normal axial pathway but fewer side branches. Widespread emphysema diagnosed. Severe panacinar emphysema present in upper and lower zones, ESG 9. C, Complete absence of vessels. Widespread emphysema diagnosed. Severe mixed emphysema in upper zone, moderate mixed in middle zone, and severe panacinar in lower zone, ESG 9.

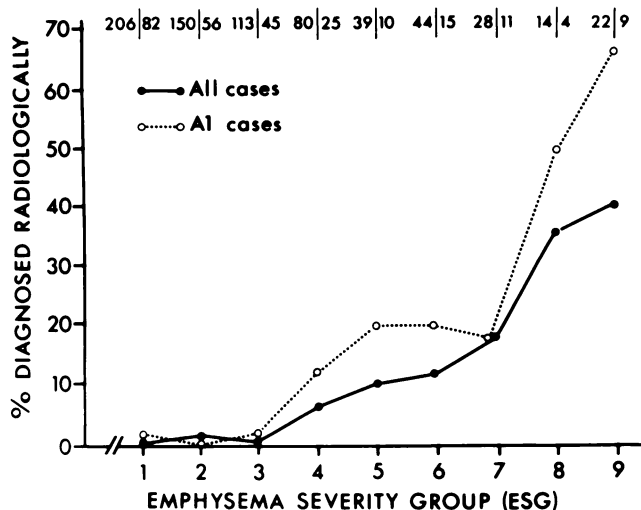


Fig. 4.—Frequency of radiologic diagnosis by emphysema severity group. Numbers at top to left of slashes indicate number in group; numbers to right of slashes indicate number of A1 cases (see text).

The performance on A1 cases is better: 16 of 20 cases were placed in exactly the same category, and 18 of 20 were regarded as positive or doubtful on both occasions.

Of the original 45 patients in ESG 7-9 whose films were thought not to show emphysema on the first reading, 41 were also thought free from emphysema on the second reading. Similarly, of the 14 A1 cases in ESG 7-9 thought free from emphysema on the first examination, only one was thought to have emphysema on the second examination.

Localized Emphysema

Localized emphysema was diagnosed radiologically 24 times in the entire group of cases. In two instances, emphysema was thought absent in the paper-mounted whole lung sections. In the 22 cases in which emphysema was considered present pathologically, radiologic examination indicated upper zonal emphysema in one or both sides in 11 instances; lower zonal emphysema in eight instances; and both upper and lower zonal emphy-

TABLE 2
Frequency of Radiologic Diagnosis of Emphysema

Category	All Cases				A1 Groups*			
	ESG 4-6		ESG 7-9		ESG 4-6		ESG 7-9	
	No.	%	No.	%	No.	%	No.	%
All cases	14/163	8.6	19/64	29.7	8/50	16.0	10/24	41.7
Chronic airflow obstruction with right ventricular hypertrophy or failure	3/8	37.5	10/19	52.6	2/4	50.0	4/8	50.0
Chronic airflow obstructive disease by symptoms and function tests	4/18	22.2	14/28	50.0	3/8	37.5	7/12	58.3
Body length measured by special study	6/28	21.4	12/28	42.9	4/9	44.4	6/12	50.0
"Other" emphysema type	7/41	17.1	8/15	53.3	2/7	28.6	2/3	66.7
Chronic bronchitis by symptoms	6/52	11.5	16/41	39.0	3/19	15.8	9/18	50.0

* Both posteroanterior and lateral films available and no significant other pulmonary disease radiologically or at necropsy.

TABLE 3
Repeatability of Radiologic Diagnosis of Emphysema

Second Reading	First Reading		
	Positive	Doubtful	Negative
All cases:			
Positive	25	3	4
Doubtful	1	1	0
Negative	6	1	0
A1 group:			
Positive	15	2	1
Doubtful	0	1	0
Negative	2	0	0

TABLE 4
Type and Distribution of Emphysema in Patients with Proven Emphysema Localized Radiologically

Emphysema Type	All Cases		A1 Group	
	Upper Zone	Lower Zone	Upper Zone	Lower Zone
Centrilobular	10	2	7	1
Panacinar	0	8	0	5
Irregular	2	0	0	0
Paraseptal	1	0	0	0
Mixed	1	1	1	1
None	2	0	0	0
Total	16	11	8	7

sema in three instances. No example of middle zonal emphysema was found. In the 22 examples of radiologically localized emphysema, the worst emphysema was present in the paper section in that zone in 14 lungs. When only the 13 A1 cases were considered, emphysema was found in all lungs on morphologic examination. In eight instances, the emphysema was clearly worse in the zones in which emphysema was diagnosed radiologically, and in two the emphysema appeared about equally severe throughout the lungs. In the three remaining cases, radiologic emphysema was thought present in the bases, but was judged less severe than the upper zones of the lungs.

Upper zonal emphysema was diagnosed 16 times in the entire series of x-rays (table 4), and centrilobular emphysema was present in 10 of the 14 cases in which emphysema was found in the lungs pathologically. In the A1 cases, centrilobular emphysema was present in seven of the eight instances. Lower zonal emphysema was diagnosed radiologically in 11 of the total cases, and panacinar emphysema was present in eight of these. In the A1 cases, panacinar emphysema was present in five of the seven instances.

Quantitative Radiologic Observations

Table 5 shows the quantitative radiologic variables in all cases with posteroanterior and lateral films. In all instances, lung dimensions were greater in males than females; the diaphragm levels were lower in relation to

TABLE 5
Quantitative Radiologic Data for All Cases with Posteroanterior and Lateral Films

Radiologic Variables	ESG 1-3		ESG 4-6		ESG 7-9	
	No. Cases	Mean	No. Cases	Mean	No. Cases	Mean
Lung Length:						
Males	145	25.0	86	26.5	29	27.8
Females	140	22.7	19	23.2	5	25.0
Retrosternal space:						
Males	145	1.83	86	2.05	30	2.55
Females	139	1.41	19	1.71	5	1.50
Diaphragm level:						
Males	146	5.74	89	6.00	32	6.41
Females	144	5.45	19	5.73	5	6.20
Heart size:						
Males	144	14.5	87	13.7	29	13.3
Females	141	13.1	19	13.1	5	11.9
Lung width:						
Males	144	29.8	86	29.8	29	29.2
Females	140	25.8	19	26.5	5	26.2

Note. — Mean values in centimeters except for diaphragm level (rib number).

the ribs as well. As emphysema becomes more severe, there is an increase in lung length, retrosternal space, and diaphragm level. The heart size decreases and lung width is unchanged. The significance of these changes in relation to the diagnosis of emphysema is discussed below.

Lung width and lung length and their multiples were related statistically to body length in both men and women. Correlation coefficients were generally in the range of .3-.4. The correlation coefficients were higher when body length was measured using the calipers. All lung dimensions were significantly larger in men than women for given stature.

Figure 5 shows the quantitative radiologic variables in the categories of increasing emphysema severity in males in the A1 category. There were insufficient females to make valid statistical comparisons. As in table 5, it is apparent that lung length, retrosternal space, and diaphragm rib number increase, heart size decreases, and lung width is unchanged as emphysema becomes worse. The differences in lung length, retrosternal space, diaphragm position, and heart size between ESG 1-3 and ESG 7-9 are significant ($P < .01$).

Lung length and diaphragm position for ESG 1-3 and ESG 4-6 are significantly different ($P < .01$ and $P < .02$, respectively). Lung length, retrosternal space, and diaphragm position for ESG 4-6 and ESG 7-9 are also significantly different ($P < .05$). We interpret these results to indicate that lung length and diaphragm position are the measurements that best recognize emphysema. Figure 5 suggests that the heart size actually increases in ESG 9, and the increase compared to ESG 7 and 8 is significant ($P < .05$). Lung width does not change with the amount of emphysema in the lungs.

Table 6 shows the frequency of the quantitative radiologic variables with varying degrees of emphysema in males in the A1 category. We have used the computer to examine the significance of combinations of retrosternal space size, diaphragm position, and lung length, since these were the most discriminating of the objective radiologic variables. No combination of criteria resulted in better recognition of moderately severe and severe emphysema than did the subjective diagnosis of emphysema, without also producing a high proportion of patients with mild or no emphysema (ESG 1-3). For example, 65.3% of patients in the A1 category in ESG 7-9 had the combination of a lung length of ≥ 26 cm in females or ≥ 27 cm in males, a retrosternal space of 2 cm or greater, and a diaphragm level between the fifth and sixth rib or below. However, 16.5% of patients in ESG 1-3 had the same combination. On the other hand, if a combination of radiologic variables was used that contained only a low proportion of patients with mild or no emphysema (e.g., lung length ≥ 26 in female or ≥ 27 in males; retrosternal space ≥ 2.5 cm; diaphragm position at or over the seventh rib), then only a relatively low proportion of patients with moderately severe and severe emphysema were detected (1.5% of patients with mild and no emphysema and 34.6% of patients with moderately severe and severe emphysema). It was also possible to choose a combination of radiologic variables that had a high probability of detecting patients with moderately severe and severe emphysema. However, the more stringent the criteria to yield a high proportion of cases with moderately severe and severe emphysema, the fewer the number of cases in the group. No workable combi-

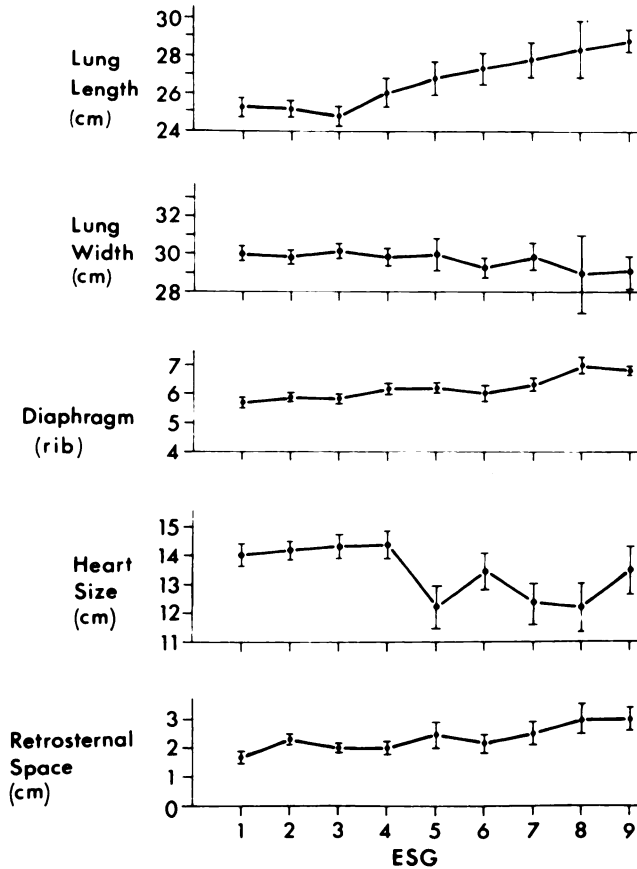


Fig. 5.—Mean values (± 1 SE) for five radiologic variables in males in A1 category.

TABLE 6
Quantitative Radiologic Data for A1 Males

Radiologic Variable (cm)	ESG 1-3		ESG 4-6		ESG 7-9	
	No.	%	No.	%	No.	%
Retrosternal space:						
≥ 2.5	32/95	33.7	19/40	47.5	13/20	65.0
≥ 3.0	24/95	25.3	14/40	35.0	11/20	55.0
≥ 3.5	5/95	5.3	4/40	10.0	6/20	30.0
Diaphragm level:						
≥ 6.0	52/96	54.2	30/40	75.0	19/20	95.0
≥ 6.5	29/96	30.2	21/40	52.5	14/20	70.0
≥ 7.0	7/96	7.3	8/40	20.0	11/20	55.0
Lung length:						
≥ 27	30/97	30.9	20/40	50.0	15/19	78.9
≥ 28	16/97	16.5	16/40	40.0	14/19	73.7
≥ 29	11/97	11.3	12/40	30.0	8/19	42.1
≥ 30	6/97	6.2	8/40	20.0	5/19	26.3

nation of variables could be produced that exceeded the subjective diagnosis of emphysema.

Limitations

Our study has a number of limitations. First, only one radiologist read the films, and thus the results apply to him only. However, he was selected because he is

recognized as a leading authority in the radiologic diagnosis of emphysema. Another deficiency is that in most instances a single paper section was used to estimate the amount of emphysema in both lungs. However, it has been shown previously that the amount of emphysema is generally equal in both lungs, and that a single section is reasonably representative of the amount of emphysema in that lung [9].

Discussion

One of us (W. M. Thurlbeck) has extensively reviewed the literature concerning the radiologic diagnosis of emphysema [10]. Thus only a brief survey of radiologic-pathologic correlation will be presented here. Since emphysema is diagnosed anatomically, only studies comparing radiographs to morphologically proven emphysema are relevant. There is conflict concerning the best criterion to diagnose emphysema. In the British literature, arterial deficiency in the outer half of the lung fields on chest films is considered the best criterion for recognizing emphysema in the lungs [11, 12]. One reference suggested that moderately severe and severe grades of emphysema were nearly always detected radiologically, whereas mild and moderate emphysema seldom produced the arterial deficiency pattern [12].

Earlier studies in North America [13, 14] indicated that the arterial deficiency pattern was less reliable and that there were significant inter- and intraobserver variations. Both these papers stressed the value of the radiologic signs of overinflation in diagnosing emphysema, and one study [13] found the sign almost invariably present in severe emphysema even when it was not clinically symptomatic. The other [14] found that the diaphragm was low and flat in only 4% of patients with no or little emphysema, while the feature was present in 94% of patients with severe emphysema. Later studies [15-17] found that radiologic evidence of overinflation was sometimes present in patients without emphysema and quite often present in patients with mild and moderate emphysema. In addition, the arterial deficiency pattern was absent in up to one-fourth of patients with severe emphysema.

Two papers [16, 17] recognized "increased markings" emphysema. In this condition the vascular markings were increased both in size and number rather than decreased. The increase was more than could be accounted for by redistribution of blood flow. When this particular pattern was used to recognize emphysema, nearly all patients with severe emphysema had radiologic abnormality [16, 17]. However, at necropsy patients with this pattern were found to have chronic airflow obstruction and cor pulmonale, irrespective of the amount of emphysema in their lungs [16], so that the pattern of increased markings also occurred in patients with mild emphysema.

Our study shows that the chest radiograph is a useful, but not very precise method of diagnosing emphysema. Occasional patients with no, trivial, or mild emphysema will be diagnosed as having emphysema, and a fairly

high proportion of patients who have severe emphysema will not be diagnosed using the radiologic criterion of arterial deficiency. However, there are fewer false positive than false negative cases. It is difficult to define false positive and false negative since expectations differ. If the desired division is the presence or absence of anatomic emphysema, then the radiologic diagnosis can be regarded as very accurate (only one doubtful false positive in 82 A1 cases) but very insensitive (only 19 of 175 lungs with emphysema were diagnosed radiologically as having emphysema). A more reasonable expectation might be that patients in ESG 1-3 should be radiologically negative and patients in ESG 7-9 positive. Using these criteria, two of 183 cases were false positive and 14 of 24 false negative.

False positive and false negative radiologic diagnoses are shown in figures 6 and 7. Figure 6 is a patient in the A1 category (ESG 3) diagnosed radiologically as having emphysema. At necropsy, only very mild panacinar emphysema was present. The patient in figure 7 died of well documented chronic airflow obstruction; the lungs were thought radiologically free from emphysema.

Fairly substantial intraobserver differences were noted when the radiographs were reinterpreted. The differences were more marked when all films were used, and absence of emphysema was more consistently recognized. These results are similar to those noted by Nicklaus et al. [14] in their intraobserver study. Since arterial deficiency was the criterion for the diagnosis of emphysema in our study, intraobserver variation was about as good as their best observer of this sign and exceeded both the overall interpretation of this sign in their study as well as the subjective diagnosis of emphysema.

An interesting aspect of our analysis is that the frequency of the radiographic diagnosis of emphysema increased within the same category of severity of anatomic emphysema if the patient had severe symptoms of chronic airflow obstruction. There are several possible explanations for this phenomenon: within the ESG categories the symptomatic patients might have more emphysema than the remaining patients; chest films might be taken more frequently in patients with chronic airflow obstruction, resulting in better quality radiographs; some particular feature of emphysema in a lung for a given ESG category makes it more likely to be associated with chronic airflow obstruction and the radiologic evidence of emphysema; and patients with symptoms might have more hypercompliant lungs than other patients in the same ESG category and would thus be more likely to have airflow obstruction and radiologically have greater evidence of overinflation. Although each of these possibilities may play a part, none appears to provide an adequate explanation at this time.

Our results show that not only is the radiologic diagnosis of emphysema made more frequently as the total amount of emphysema in the lung increases but also that the radiologic diagnosis of emphysema indicates the position within the lung where emphysema is most severe. It also helps to indicate the type of emphysema

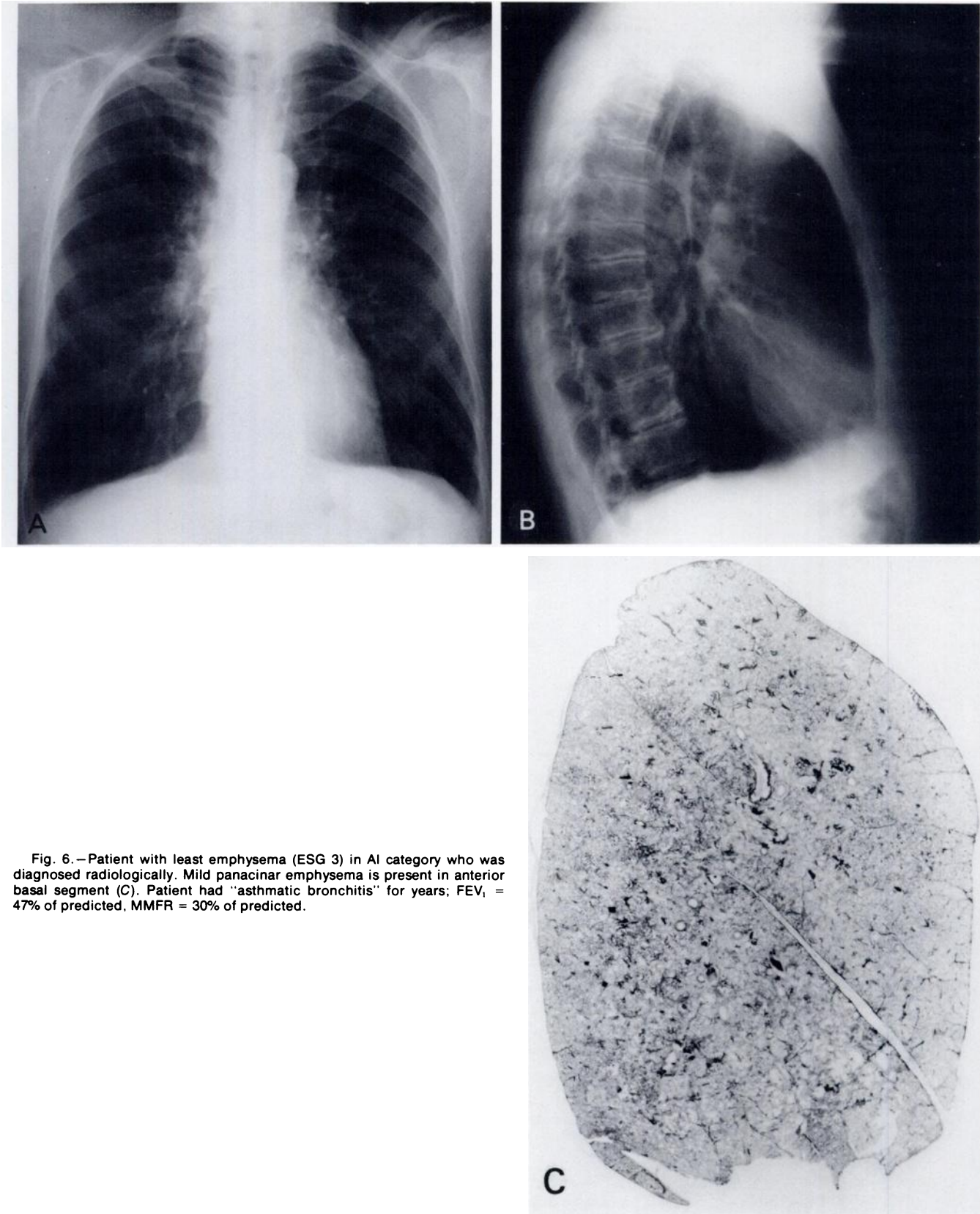


Fig. 6.—Patient with least emphysema (ESG 3) in AI category who was diagnosed radiologically. Mild panacinar emphysema is present in anterior basal segment (C). Patient had "asthmatic bronchitis" for years; FEV₁ = 47% of predicted, MMFR = 30% of predicted.

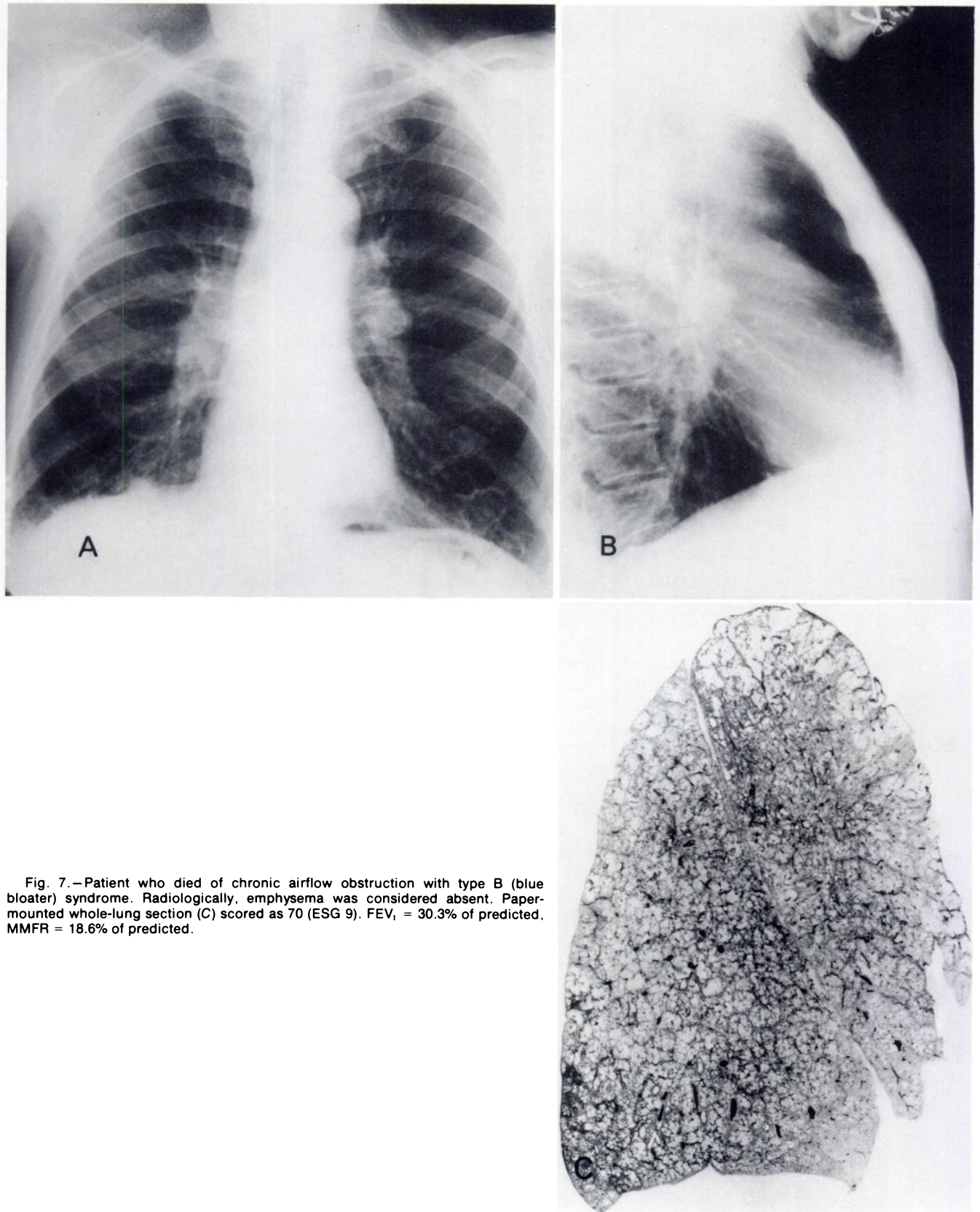


Fig. 7.—Patient who died of chronic airflow obstruction with type B (blue bloater) syndrome. Radiologically, emphysema was considered absent. Paper-mounted whole-lung section (C) scored as 70 (ESG 9). $FEV_1 = 30.3\%$ of predicted, $MMFR = 18.6\%$ of predicted.

present. Anatomically, emphysema was usually worst in the zones indicated radiologically.

Of more interest is the correlation between radiologic localization of severity and the type of emphysema. Our data clearly show that when emphysema was diagnosed radiologically in the upper zones of the lung, centrilobular emphysema was usually found. This was particularly true of the A1 cases where centrilobular emphysema was found in seven of eight instances. Conversely, when emphysema was diagnosed in the lower zones, panacinar emphysema was usually found in the lungs. In part, this observation reflects the distribution of emphysema in the lung; centrilobular emphysema is predominantly a disease of the upper zones of the lung. In this series and in many others, centrilobular emphysema was encountered about eight times more frequently in the upper one-third of the lung than the lower third (see NAPS material). Similarly, panacinar emphysema is predominantly a lower zonal condition: in this series it was found about twice as often in the lower third of the lung compared to the upper third. However, our data also show that panacinar emphysema is more likely to be diagnosed radiologically than either centrilobular emphysema or other forms (see NAPS material). The increased radiographic recognition of panacinar emphysema did not result because the panacinar emphysema was more severe than centrilobular emphysema. Within the limitations of the scoring system, the average score of centrilobular emphysema in the upper zones of the lungs was about the same as that of panacinar emphysema in the lower zones.

It is of interest that the objective radiologic measurements could not predict the amount of emphysema in the lungs better than the subjective diagnosis of emphysema, despite access to computing facilities that could examine several thousand combinations of two or more objective measurements. It should also be noted that single criteria such as a low diaphragm or an enlarged retrosternal space were poor discriminators for the presence of emphysema and were often abnormal in patients with little or no emphysema. As pointed out in the results section, various combinations of size and retrosternal space, diaphragm position, and lung length could be found in which a high proportion of patients had moderately severe and severe emphysema. Table 5 and figure 5 of our statistical analysis of these data show that lung length and diaphragmatic position were the best discriminators in our study, followed by size of the retrosternal space; heart size was a poor discriminator, and lung width was of no value.

We are unable to add any further information about "increased markings emphysema." Regrettably, most of the films used in the study [16] with a different radiologist (R. G. Fraser) had been discarded, so we were unable to make an interobserver comparison. The radiologist in the present study does not recognize this category. However, it should be noted that he diagnosed emphysema more frequently in patients with obvious pulmonary hypertension and cor pulmonale than in the group

as a whole. It is this category in which the increased markings form of emphysema was found to be commonly present in the previous study. It would appear that the majority of patients with emphysema and cor pulmonale still have a characteristic arterial deficiency pattern as interpreted by the present radiologic observer. This agrees with the previous observations [16]: about half of patients with severe emphysema had the arterial deficiency pattern alone, and about half of the remainder had a mixed arterial deficiency and increased marking pattern.

Our study indicates that the radiologic sign of a small vertical heart is of limited value in recognizing emphysema. This finding is in keeping with our observation that right ventricular hypertrophy is more common in patients with severe emphysema [16]. Thus there is apparent conflict with the concept that patients with severe emphysema have small hearts whereas patients who have "bronchitis" as the primary cause of chronic airflow obstruction have large right ventricles. We have reviewed the evidence for this notion at length elsewhere [10] and have pointed out that it is unsupported by available information.

Lung length and lung width, being one-dimensional functions, vary with the cube root of lung volume, so that the change in these linear dimensions is relatively small compared to the lung volume change. For given stature, lung dimensions were smaller in women than men. While this is not surprising since women have smaller lung volumes than men of comparable stature [18], it gives our measurements added credibility.

REFERENCES

1. Felson B: *Chest Roentgenology*. Philadelphia, Saunders, 1973
2. Scott RB (ed): *Price's Textbook of the Practice of Medicine*, 11th ed. London, Oxford University Press, 1973
3. Reid L: *The Pathology of Emphysema*. London, Lloyd-Luke, 1967
4. Burrows B, Fletcher CM, Heard BE, Jones NL, Wooltiff JS: The emphysematous and bronchial types of chronic airways obstruction: a clinicopathological study of patients in London and Chicago. *Lancet* 1:830-835, 1966
5. Gough J, Wentworth JE: Thin sections of entire organs mounted on paper. *Harvey Lect* 53:182, 1958
6. Thurlbeck WM, Dunnill MS, Hartung W, Heard BE, Heppleston AG, Ryder RC: A comparison of three methods of measuring emphysema. *Hum Pathol* 1:215-226, 1970
7. Simon G, Reid L, Tanner JM, Goldstein H, Benjamin B: Growth of radiologically determined heart diameter, lung width, and lung length from 5-19 years, with standards for clinical use. *Arch Dis Child* 47:373-381, 1972
8. Simon G: *Principles of Chest X-ray Diagnosis*. London, Butterworth, 1971
9. Thurlbeck WM: The geographic pathology of pulmonary emphysema and chronic bronchitis. II. Subjective assessment of emphysema. *Arch Environ Health* 14:21-30, 1967
10. Thurlbeck WM: *Chronic Airflow Obstruction in Lung Disease*. Philadelphia, Saunders, 1976
11. Laws JW, Heard BE: Emphysema and the chest film: a

- retrospective radiological and pathological study. *Br J Radiol* 35:750-761, 1962
12. Reid L, Millard FJC: Correlation between radiological diagnosis and structural lung changes in emphysema. *Clin Radiol* 15:307-311, 1964
 13. Sutinen S, Christoforidis AJ, Klugh GA, Pratt PC: Roentgenologic criteria for the recognition of nonsymptomatic pulmonary emphysema: correlation between roentgenologic findings and pulmonary pathology. *Am Rev Resp Dis* 91:69-76, 1965
 14. Nicklaus TM, Stowell DW, Christiansen WR, Renzetti AD Jr: The accuracy of the roentgenologic diagnosis of chronic pulmonary emphysema. *Amer Rev Respir Dis* 93:889-899, 1966
 15. Katsura S, Martin CJ: The roentgenologic diagnosis of anatomic emphysema. *Amer Rev Respir Dis* 96:700-706, 1967
 16. Thurlbeck WM, Henderson JA, Fraser RG, Bates DV: Chronic obstructive lung disease: a comparison between clinical, roentgenologic, functional and morphologic criteria in chronic bronchitis, emphysema, asthma, and bronchiectasis. *Medicine* 49:81-145, 1970
 17. Boushy SF, Aboumrad MH, North LB, Helgason AH: Lung recoil pressure, airway resistance, and forced flows related to morphologic emphysema. *Am Rev Respir Dis* 104:551-561, 1971
 18. Bates DV, Macklem PT, Christie RV: *Respiratory Function in Disease*. Philadelphia, Saunders, 1971